



E-ISSN: 2708-0064  
P-ISSN: 2708-0056  
JCRSI 2020; 2(1): 01-03  
Received: 03-05-2020  
Accepted: 04-06-2020

**Saima Khan**  
Consultant Pathologist,  
Department of Pathology,  
Charak Diagnostic Centre,  
Lucknow, Uttar Pradesh,  
India

**Zaid Ahmad Khan**  
Senior Resident, Department  
of Surgery, Motilal Nehru  
Medical College, Allahabad,  
Uttar Pradesh, India

**Jowairiah Hassan**  
Senior Resident, Department  
of Pathology, Jawaharlal  
Nehru Medical College,  
Aligarh, Uttar Pradesh, India

**Corresponding Author:**  
**Saima Khan**  
Consultant Pathologist,  
Department of Pathology,  
Charak Diagnostic Centre,  
Lucknow, Uttar Pradesh,  
India

## When it comes to inflammatory lesions, size does not matter: A rare case of large xanthogranulomatous oophoritis mimicking malignancy

**Saima Khan, Zaid Ahmad Khan and Jowairiah Hassan**

### Abstract

Xanthogranulomatous inflammation of ovary is a non-neoplastic, rare chronic process in which the ovary is damaged by massive cellular infiltration of foamy histiocytes admixed with plasma cells, fibroblasts, multinucleated giant cells, neutrophils, and necrotic foci. The etiology remains unknown, but it does share the histopathological findings of xanthogranulomatous change occurring in different organs, including the gallbladder and kidney. The current case was a 24 year old female presenting with an ovarian mass with high suspicion of malignancy on clinicoradiological evaluation. A vigilant histopathological study was carried out and the final diagnosis of xanthogranulomatous oophoritis was established.

**Keywords:** inflammatory lesions, large xanthogranulomatous, non-neoplastic

### Introduction

#### Background

Xanthogranulomatous inflammation is a rare non neoplastic chronic inflammatory process that leads to destruction of tissue and striking replacement by cellular infiltrate comprising of lipid-containing macrophages, lymphocytes, plasma cells, multinucleated giant cells and neutrophils<sup>[1]</sup>. The etiology and pathogenesis remains unclear, although this unusual disease has a gross and microscopic appearance similar to xanthogranulomatous change occurring in other organs, such as the gallbladder, kidney, bladder, bone, testis and vagina. Involvement of female genital tract is very uncommon and is usually limited to endometrium with only a few cases been reported involving the ovary<sup>[2]</sup>. Its presentation as a mass lesion in pelvic cavity and invasion of adjoining tissue can mimic a neoplastic lesion clinically, radiologically as well as on gross examination<sup>[3]</sup>

The reported case here is of xanthogranulomatous oophoritis in a married 24 year female, which was clinically and radiologically misdiagnosed as an ovarian neoplasm owing to its size. Histopathological findings quite evidently revealed characteristic features of xanthogranulomatous oophoritis.

#### Case Presentation

A 24 year-old married female with one child presented with the complaints of sharp pain in abdomen on and off along with heavy irregular menstrual cycles for 6 months. On examination, there was tenderness in the lower abdomen on palpation and a firm left adnexal mass could be felt. Her blood investigations revealed microcytic hypochromic anemia, elevated total leucocyte counts and ESR of 40mm/hr. other investigations were ordered, LFT, RFT, tumor markers and urine pregnancy test which came back within normal range. Contrast-enhanced computed tomography abdomen was performed, which showed a left adnexal cystic mass causing displacement of uterus. Right ovary showed normal features with no prominent abnormality. A diagnosis of ovarian neoplasm was made and the patient was taken up for exploratory laparotomy with salpingo-oophorectomy. Intraoperatively, no ascites or omental deposits were observed. Specimen was sent for histopathological evaluation.

On Gross examination, the right ovarian cyst measured 14 cm × 10 cm × 7 cm and was filled with foul smelling, dirty yellowish fluid and cheesy material. Cyst was unilocular and inner lining was brownish yellow and shaggy which replaced the entire ovary [Figure 1]. Wall thickness varied from 0.5 to 1cm.

Microscopic evaluation of the cyst wall revealed replacement and destruction of the ovarian stroma by dense inflammatory exudate comprising of sheets of foamy macrophages, lymphocytes, plasma cells and some neutrophils along with areas of necrotic debris. No atypical cells were identified. Microsections from the fallopian tube were unremarkable. A final diagnosis of xanthogranulomatous oophoritis was established and signed off. The patient was postoperatively given intravenous antibiotics for 5 days then made an uneventful recovery and was discharged on the 7th postoperative day.

### Discussion and Conclusion

Xanthogranulomatous inflammation routinely and most commonly affects kidney and gall bladder [4]. Other organs affected by this type of inflammation are stomach, anorectal area, urinary bladder, testis, epididymis and bone [5]. The female genital tract is very rarely affected by xanthogranulomatous inflammation and is mostly confined to endometrium. The review of literature revealed only a few reported cases of xanthogranulomatous oophoritis from India with the mean age of around 31 years [6]. The clinical presentations include pain in abdominal pain and mass, fever, menorrhagia, anemia and anorexia. Examination reveals adnexal mass with tenderness. Laboratory tests show anemia with elevated ESR and raised white blood cell count. Radiological findings may closely simulate a malignant ovarian neoplasm, due to adhesions in the peritoneum and the involvement of adjoining organs. On gross examination, the involved ovary is largely replaced by a solid, yellow lobulated mass, sometimes involving adjacent organs, thereby mimicking malignancy. Further histopathological evaluation microscopically reveals diffuse infiltration in form of sheets of foamy cells admixed with inflammatory cells such as lymphocytes, plasma cells, neutrophils with or without multinucleated giant cells [7]. The yellow color on gross evaluation is due to foamy histiocytes (xanthoma cells) containing abundant lipid-laden cytoplasm having clear vacuolated appearance.

The etiopathogenesis of xanthogranulomatous oophoritis remains an enigma however many theories have been put forth such as theory of association with Pelvic inflammatory disease, use of IUCD, endometritis, inborn lipid metabolism of macrophages and drugs. So far, the most promising and accepted theory is of infection which is further supported by clinical evidence of infection and growth of bacteria such as *E. Coli*, *Bacteroides fragilis*, *Proteus* and *Salmonella typhi* in the tissue which can be diagnosed by culture [8, 9].

Several differential diagnosis of xanthogranulomatous oophoritis should be considered including malakoplakia, tuberculosis and fungal infections most commonly which need to be ruled out by culture and special stains for the causative organisms. Malakoplakia shows cytoplasmic concentric calcific bodies (Michaelis-Gutmann bodies) on H and E examination followed by PAS stain [10].

Frozen section is particularly beneficial in diagnosis of xanthogranulomatous oophoritis which present as a diagnostic dilemma and for intraoperative management so as to reduce unnecessary unwarranted and extensive surgery. The treatment of choice for xanthogranulomatous oophoritis remains oophorectomy.

In conclusion, xanthogranulomatous oophoritis is a rare lesion whose clinical manifestations, imaging results and gross features may mimic ovarian malignancy. Thus, a

preoperative diagnosis of this entity and proper utilization of frozen section may be opted for in selected cases which masquerade as adnexal neoplasm in order to avoid radical surgical treatment particularly in females of younger age group.

### Declarations

#### Ethics Approval and Consent to Participate

The authors certify that we have obtained all the appropriate patient consent forms. The patient has given her consent for her images and other clinical information to be used in the journal. The patients understand that their names and initials will not be published and efforts will be made to conceal their identity.

Consent for publication NA

Availability of data and materials NA

Competing interests NA

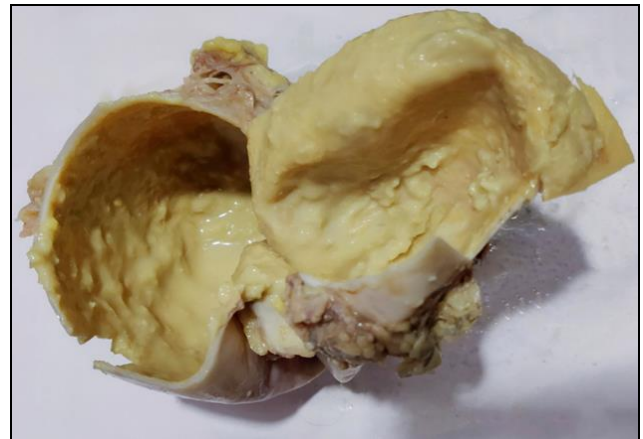Funding NA

#### Authors' contributions

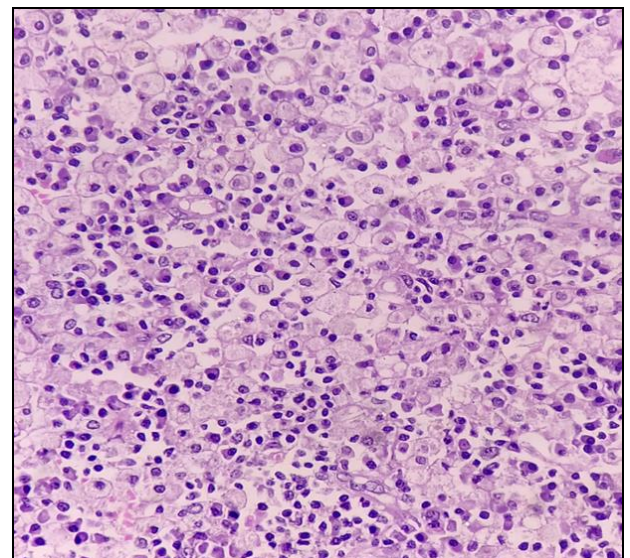
Saima Khan-Conceptualization, Methodology, Original draft preparation

Zaid Ahmad Khan-Visualization, Investigation, Writing-Reviewing and Editing

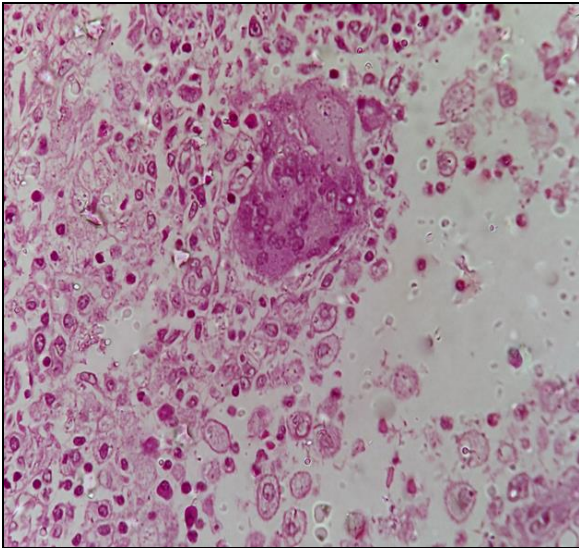
Jowairiah Hassan-Writing-Reviewing and Editing, Data curation



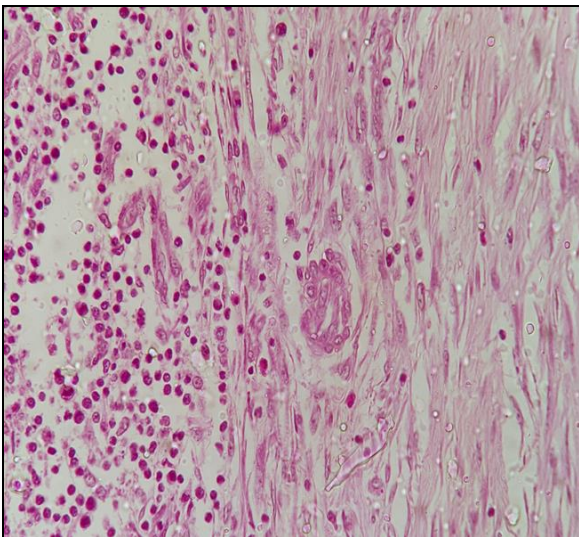
**Fig 1:** Gross macroscopic pathological specimen of right ovary



**Fig 2:** Microsections from ovarian mass shows abundant foamy macrophages, along with lymphoplasmacytic cells (H and E,  $\times 40$ )



**Fig 3:** Microsections show foamy macrophages multinucleated giant cell in the centre (H and E,  $\times 40$ )



**Fig 4:** Microsections show ovarian parenchyma with dense lymphoplasmacytic cells (H and E,  $\times 40$ )

6. Shukla S, Pujani M, Singh SK, Pujani M. Xanthogranulomatous oophoritis associated with primary infertility and endometriosis. *Indian J Pathol Microbiol.* 2010; 53:197-198.
7. Kalloli M, Bafna UD, Mukherjee G, Devi UK, Gurubasavangouda, Rathod PS. A rare xanthogranulomatous oophoritis presenting as ovarian cancer. *Online J Health Allied Sci.* 2012; 11:11.
8. Xiang-sheng Zhang, Hong-yan Dong, Lei-lei Zhang, Mohamed Mokhtar Desouki, Chengquan Zhao. Xanthogranulomatous Inflammation of the Female Genital Tract: Report of Three Cases. *Journal of Cancer.* 2012; 3:100-106.
9. Gray Y, Libbey NP. Xanthogranulomatous salpingitis and oophoritis: A case report and review of the literature. *Arch Pathol Lab Med.* 2001; 125:260-263.
10. Tanwar H, Joshi A, Wagaskar V, Kini S, Bachhav M. Xanthogranulomatous Salpingo Oophoritis: The Youngest Documented Case Report. *Case Reports in Obstetrics and Gynecology.* 2015; 3:01-04.

## References

1. Sun Ho Kim, Seung Hyup Kim, Dal Mo Yang, Kyeong A Kim. Unusual causes of tubo-ovarian abscess: CT and MRI Imaging Findings. *Radiographics.* 2004; 24(6):1575-1589.
2. Jung SE, Lee JM, Lee KY, Han KT, Hahn ST. Xanthogranulomatous oophoritis: MR imaging findings with pathologic correlation. *AJR Am J Roentgenol.* 2002;178:749-51.[PubMed]
3. Mahesh Kumar U, Potekar RM, Yelikar BR, Pankaj Pande. Xanthogranulomatous oophoritis-masquerading as ovarian neoplasm. *Asian J Pharm and Sci.* 2012; 2(2):308-309.
4. Mittal BV, Badhe BP. Xanthogranulomatous pyelonephritis (a clinico-pathological study of 15 cases): *Journal of Postgraduate Medicine.* 1989; 35(4):209-214.
5. Zhang XS, Dong HY, Zhang LL, Desouki MM, Zhao C. Xanthogranulomatous inflammation of the female genital tract: Report of three cases. *J Cancer.* 2012; 3:100-6.[PMC free article] [PubMed]